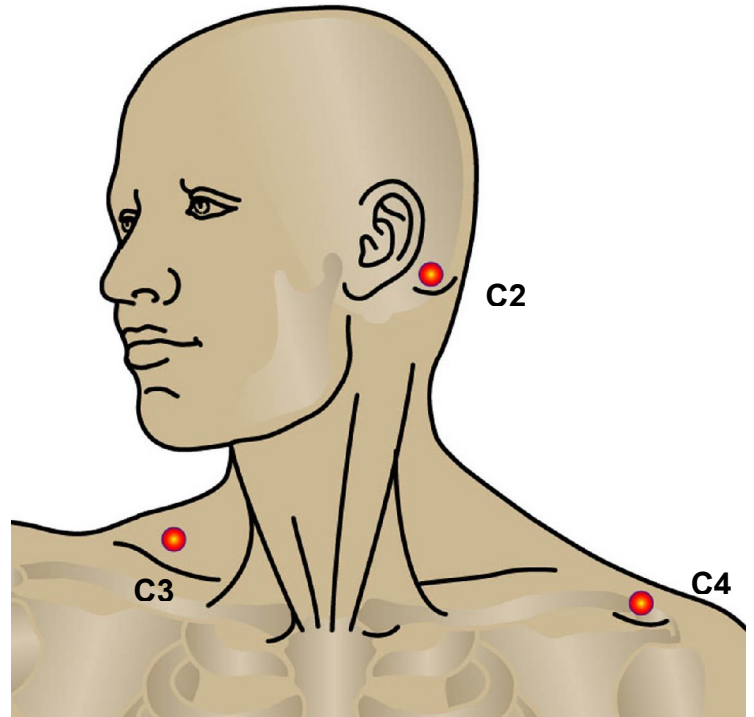


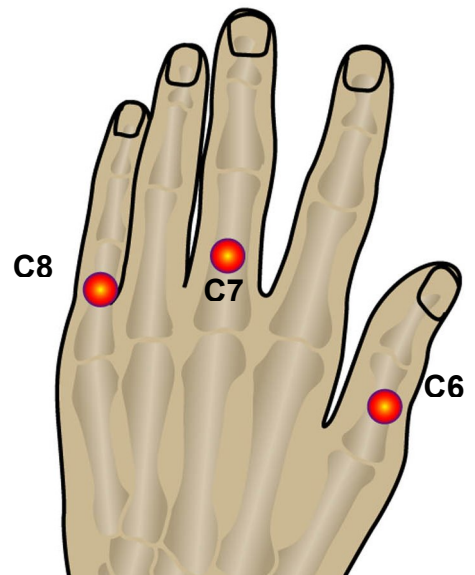
International Standards for the Classification of Spinal Cord Injury

Key Sensory Points

- C2** At least one cm lateral to the occipital protuberance at the base of the skull. Alternately, it can be located at least 3 cm behind the ear.
- C3** In the supraclavicular fossa, at the midclavicular line.
- C4** Over the acromioclavicular joint.

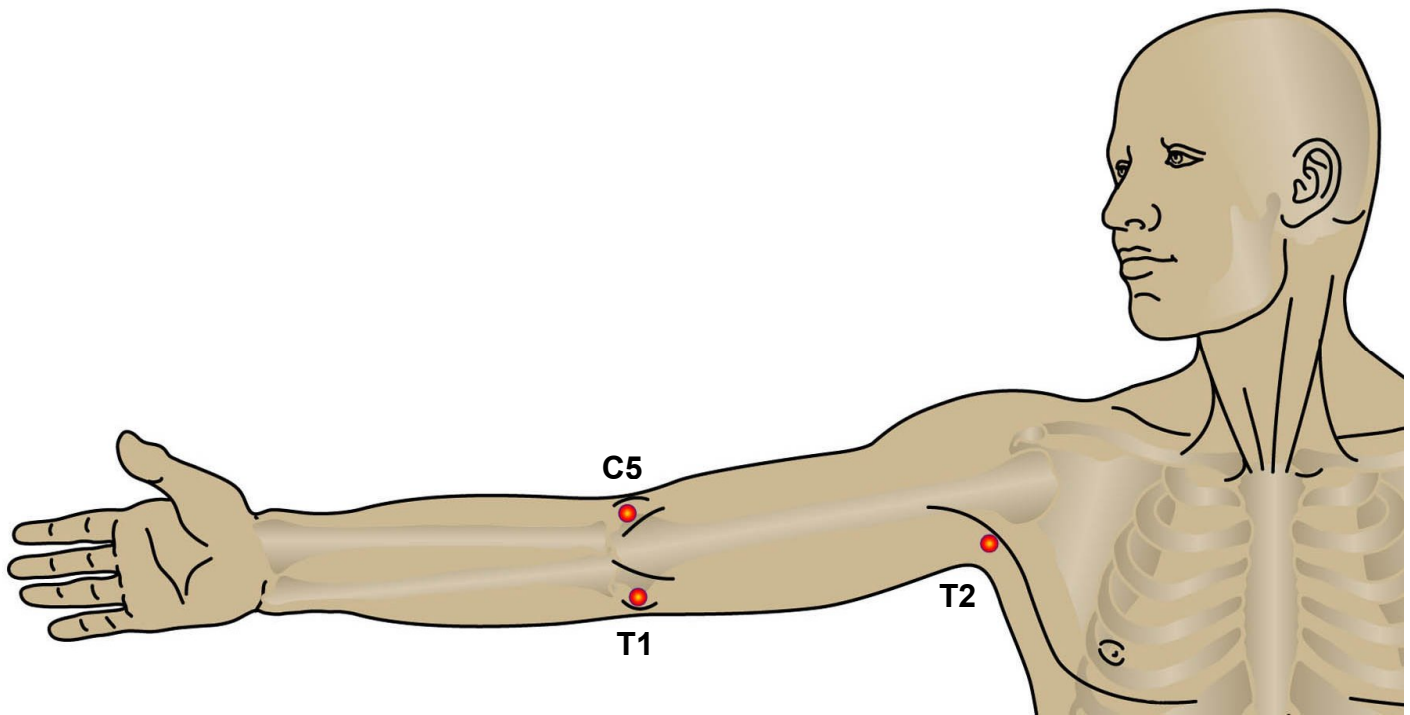


- C5** On the lateral (radial) side of the antecubital fossa just proximal to the elbow (see image below).
- C6** On the dorsal surface of the proximal phalanx of the thumb.
- C7** On the dorsal surface of the proximal phalanx of the middle finger.
- C8** On the dorsal surface of the proximal phalanx of the little finger.



International Standards for the Classification of Spinal Cord Injury

Key Sensory Points



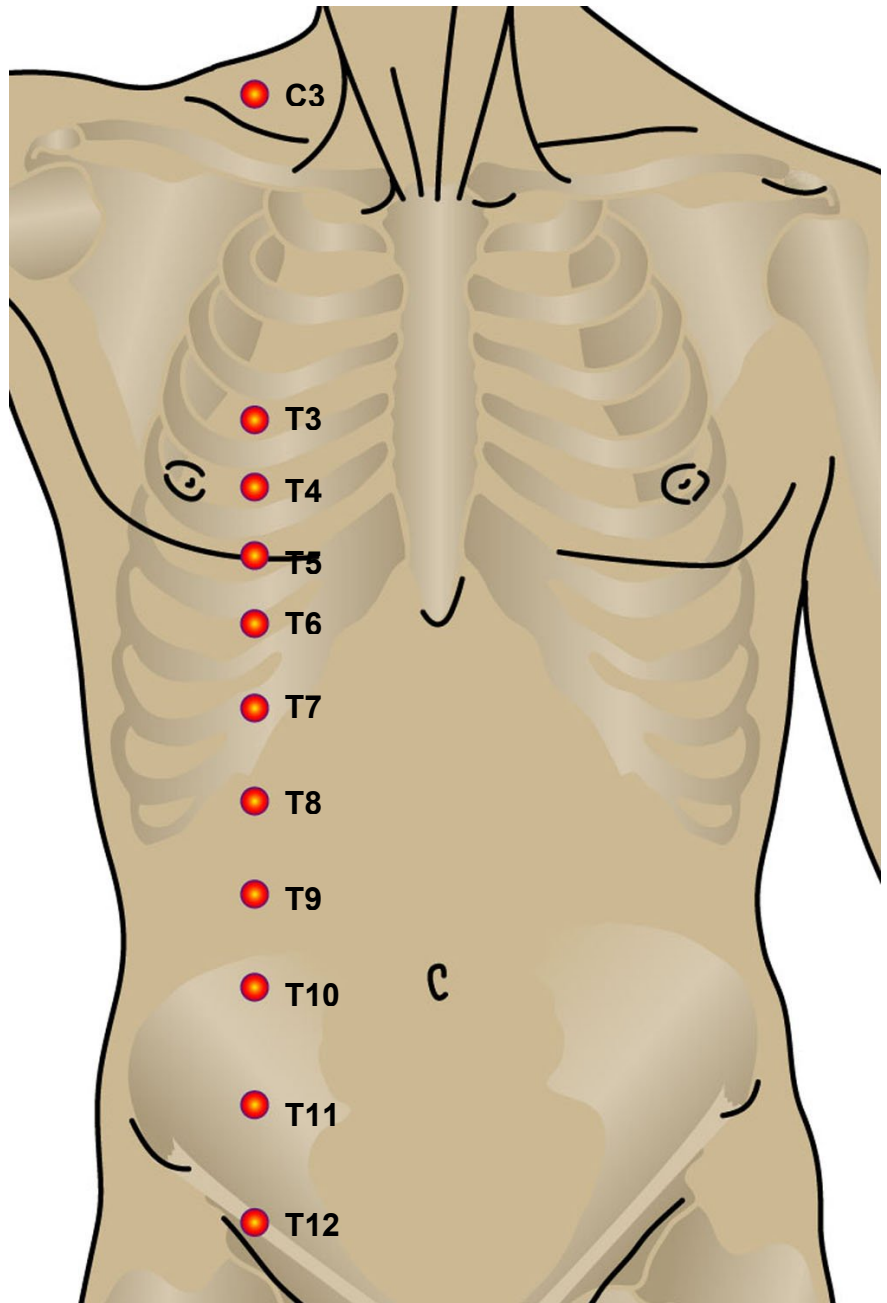
T1 On the medial (ulnar) side of the antecubital fossa, just proximal to the medial epicondyle of the humerus.

T2 At the apex of the axilla.

International Standards for the Classification of Spinal Cord Injury

Key Sensory Points

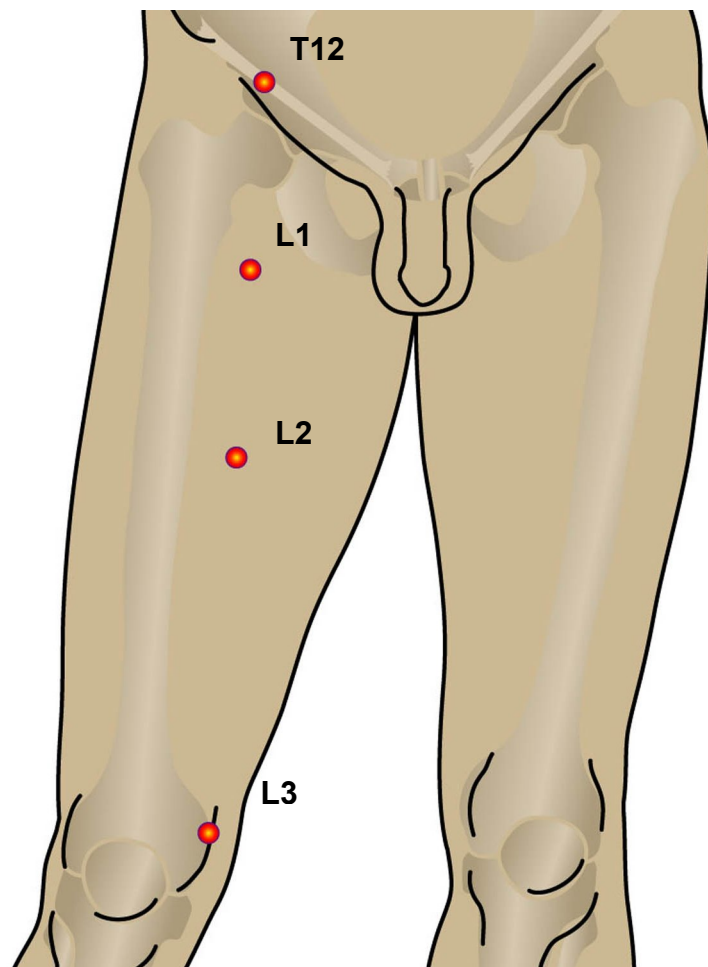
- T3** At the midclavicular line and the third intercostal space, found by palpating the anterior chest to locate the third rib and the corresponding third intercostal space below it.
- T4** At the midclavicular line and the fourth intercostal space, located at the level of the nipples.
- T5** At the midclavicular line and the fifth intercostal space, located midway between the level of the nipples and the level of the xiphisternum.
- T6** At the midclavicular line, located at the level of the xiphisternum.
- T7** At the midclavicular line, one quarter the distance between the level of the xiphisternum and the level of the umbilicus.
- T8** At the midclavicular line, one half the distance between the level of the xiphisternum and the level of the umbilicus.
- T9** At the midclavicular line, three quarters of the distance between the level of the xiphisternum and the level of the umbilicus.
- T10** At the midclavicular line, located at the level of the umbilicus.
- T11** At the midclavicular line, midway between the level of the umbilicus and the inguinal ligament.
- T12** At the midclavicular line, over the midpoint of the inguinal ligament.



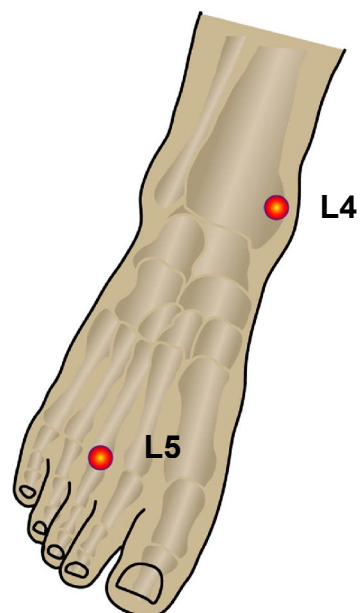
International Standards for the Classification of Spinal Cord Injury

Key Sensory Points

- L1** Midway between the key sensory points for T12 and L2.
- L2** On the anterior-medial thigh, at the midpoint drawn on an imaginary line connecting the midpoint of the inguinal ligament and the medial femoral condyle.
- L3** At the medial femoral condyle above the knee.



- L4** Over the medial malleolus.
- L5** On the dorsum of the foot at the third metatarsal phalangeal joint.

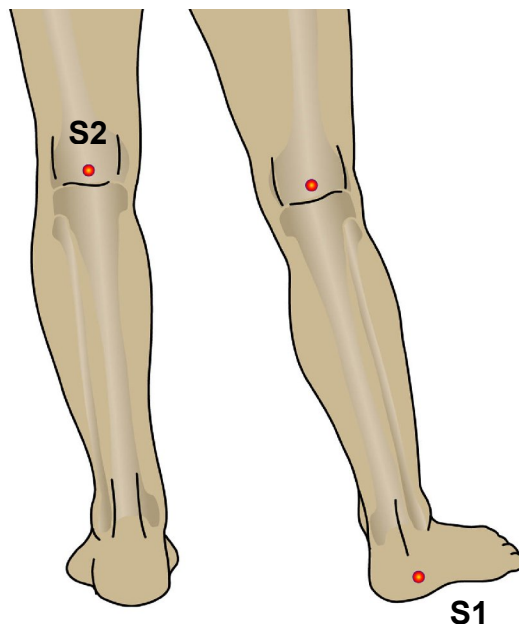


International Standards for the Classification of Spinal Cord Injury

Key Sensory Points

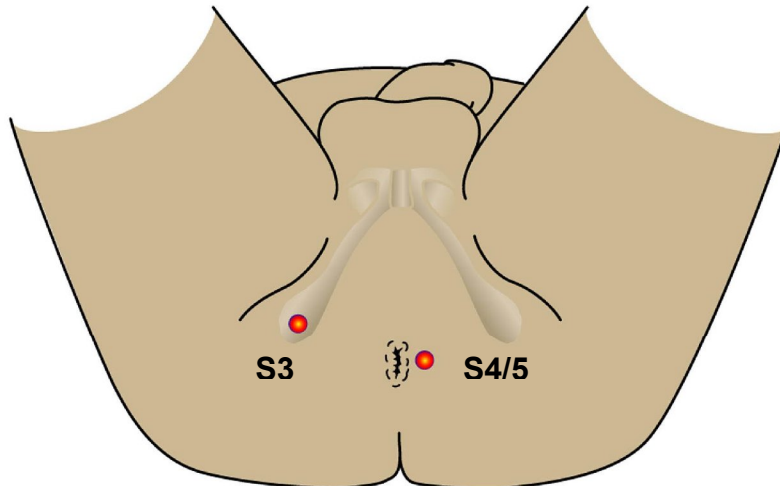
S1 On the lateral aspect of the calcaneus.

S2 At the midpoint of the popliteal fossa.



S3 Over the ischial tuberosity or infragluteal fold (depending on the patient their skin can move up, down or laterally over the ischii).

S4/5 In the perianal area, less than one cm. lateral to the mucocutaneous junction.



International Standards for the Classification of Spinal Cord Injury

Key Sensory Points

